

# Long Term Recovery of Diaphragmatic Function in a Patient with Unilateral Diaphragmatic Pacemaker

Salim Surani<sup>\*1</sup>, Eva Elizabeth Ayala<sup>2</sup>, Myriah McMillan<sup>3</sup>, Elizabeth Sablonte<sup>3</sup> and Pilar Acosta<sup>4</sup>

<sup>1</sup>Texas A&M University, Texas, USA

<sup>2</sup>Christus Spohn Hospital, Corpus Christi, Texas, USA

<sup>3</sup>University of North Texas Health Science Center, TCOM, USA

<sup>4</sup>Dorrington Medical Associates, USA

**Abstract:** Diaphragmatic pacing, also known as electrophrenic respiration or phrenic pacing has been used for quite some time in patients with respiratory failure due to diaphragmatic paralysis. We present a case of patient with respiratory insufficiency due to unilateral phrenic nerve injury as a result of radiation therapy for breast cancer. The patient had a diaphragmatic pacer inserted, with significant recovery on her symptoms. Three years after this procedure, the patient recovered her phrenic nerve function, and this was confirmed by nerve conduction study.

**Keywords:** Diaphragmatic pacing, respiratory failure, diaphragm paralysis.

The thoracic diaphragm muscle plays an integral role on the mechanics of breathing. Injury to the thoracic diaphragm can compromise the breathing and may conduct the patient to respiratory failure requiring mechanical ventilation. Injury to diaphragm can result from various etiologies such as blunt injury, radiation therapy, and iatrogenic complication during surgery. In the event of respiratory failure mechanical ventilation has been applied as the life saving therapy. But more frequently, over the last few decades diaphragmatic pacemakers have been used in these patients. We had published a case report of a 60 year female with unilateral diaphragmatic injury that got successful treatment with unilateral diaphragmatic pacemaker [1]. In this paper, we report the results after a three year follow up of this patient, specially the recovery of function of the thoracic diaphragm muscle.

## CASE REPORT

A 63-year old Caucasian female presented three years ago with the chief complaint of progressive shortness of breath, which exacerbated on exertion of only few feet. The patient had remarkable past medical history for stage 1 breast cancer. She had a tumor on the right breast, for which she was treated with modified radical mastectomy, and radiation therapy seven years prior to this presentation. Since after her surgery she became progressively more short of breath. She also received estrogen receptor modulator (tamoxifen) therapy for few years. Her clinical course was complicated by diagnosis of multiple myeloma which responded poorly to chemotherapy. Because of her compromised respiratory status and dyspnea on exertion of only few feet, she was not considered to be a suitable candidate for stem cell transplantation. She was then referred to us. During her diagnostic work up for dyspnea she was found to have a right hemi-diaphragm paralysis which was confirmed by fluoroscopy. She also underwent pulmonary function test which revealed FEV1

of 0.84 liters and DLCO of 66%. Arterial blood gas revealed the PaO<sub>2</sub> to be 83 on nasal cannula at 2 liter/minute. The nerve conduction study done after this finding, showed the absence of motor response in the right phrenic nerve with no distal motor latency recordable (Fig. 1). The patient underwent placement of a right diaphragmatic pacemaker, which was successful. The patient showed significant improvement in her oxygenation status, dyspnea and overall pulmonary status. In view of her improved respiratory status she was then considered to be a good candidate for stem cell transplantation. She underwent successful stem cell transplantation for multiple myeloma. Three years later, patient presented to our clinic with no dyspnea on exertion even with heavy exercise, and there was improvement in oxygenation and pulmonary status. She stated that she felt her diaphragm was moving even when she turns off her pacemaker. The nerve conduction study was repeated and the results were compared to the ones of the previous study done 3 years back. The new results showed a regain in function of the right phrenic nerve. The results showed a compound motor action potential of the right phrenic nerve that had higher amplitude when compared to the left phrenic nerve. The duration of the action potential was also increased, suggesting a clear regeneration of right phrenic nerve (Fig. 2).

## DISCUSSION

The use of diaphragmatic pacing by phrenic nerve stimulation has been described in medicine for several decades. The diaphragmatic pacing is also known as phrenic pacing or electrophrenic nerve pacing, is the stimulation of phrenic nerves with electric current *via* an implanted pacemaker which results in the contraction of diaphragm muscle. One of the first ones who noticed the movement of the diaphragm with phrenic nerve stimulation was Caldani in 1786. It was in 1898, when Puchenne described the function of the phrenic nerve and that it could stimulate normal respiration [2]. Almost 75 years later, Glenn and colleagues reported their first pacemaker implant in a quadriplegic patient who was ventilator dependant. After this description current con-

\*Address correspondence to this author at the Texas A&M University, 613 Elizabeth Street, Suite 813, Corpus Christi, Texas, TX 78404, USA; E-mail: srsurani@hotmail.com

cepts in surgical technique and equipment were developed and are still used today in diaphragmatic pacemaker implantation [2, 3].

There are selected indications for diaphragmatic pacing and it includes the following: idiopathic central alveolar hypoventilation, organic lesions of the brain stem, and lesions of the cervical cord, certain neuromuscular diseases, and some cases of COPD (Chronic Obstructive Pulmonary Disease) [2]. There are some specific requirements in order for the diaphragmatic pacer to work. The LMN (lower motor neurons) and the phrenic nerves must be intact. The cell bodies of this nerve in segments C3, C4 and C5 of the spinal cord must be viable [2, 3]. When the C3-C5 cell bodies are spared there is an injury to the LMN; the artificial respiratory function can be maintained by electrical stimulation of the phrenic nerves [4]. Phrenic nerve viability is tested by measuring the excursion of each hemi diaphragm after percutaneous stimulation. The viability is determined by a diaphragmatic excursion greater than 5 cm, while non viability is indicated by no response of the diaphragm [2].

There are some medical conditions that contraindicate diaphragmatic pacing, and it includes the following: prior implantation of another electronic device such as a cardiac pacemaker, nonviable phrenic nerves, progressive neurologic disease, and poor lung compliance secondary to severe parenchymal lung disease or significant thoracic cage deformities [2].

There are several etiologies of phrenic nerve injury which includes trauma to the spinal cord above the level of the sixth cervical vertebrae (C6), tumor invasion, radiation injury, hemorrhage, infarction, syringomyelia, certain demyelinating diseases, or injury during coronary artery revascularization [2, 3, 5]. Damage to the phrenic nerve leads to diaphragmatic paralysis which in turn leads to diaphragmatic weakness and a reduction in inspiratory muscle capacity and lung volume, thus impairing respiratory muscle endurance and producing exertional dyspnea [6]. Furthermore, diaphragmatic denervation results in muscle fibrosis, fiber atrophy and necrosis [6].

The pacing is achieved by implantation of receiver which is a small electronic device, approximately ¼" thick, which receives radio-frequency energy and converts it into electrical impulse, which stimulate diaphragm. The implanted electrode is a highly flexible stainless steel wire, with a platinum nerve contact at one end and connected to the receiver at the other end. An external antenna is worn over each implanted receiver, which send signal from transmitter to receiver transcutaneously. DiMarco also described the technique by which the phrenic nerves can be activated by placement of intramuscular electrodes *via* laparoscopic surgery [7].

Once the pacer has been implanted, the diaphragm must be conditioned to work with the pacer. The conditioning process can be accomplished with the aid of mechanical ventilation [8]. Conditioning entails using low frequency stimulation over a period of months to resist fatigue of the diaphragm and can gradually restore diaphragms with disuse atrophy [3, 9]. During the conditioning process, the fast

contracting fibers, which are susceptible to fatigue (type II fibers), are converted to slow contracting fatigue resistant fibers (type I fibers) thus enabling permanent ventilatory support with the diaphragmatic pacer [3, 10].

Several cases of phrenic nerve regeneration have been reported. In patients with bilateral diaphragm paralysis secondary to neuralgic amyotrophy, Hughes showed evidence of patients recovering diaphragm strength beginning at 2 years after disease diagnosis [11]. Strakowski *et al.* reported on three patients who recovered phrenic nerve function within 6 to 11 months following cervical spinal cord injury causing the need for mechanical ventilation [12]. Pearce G. Wilcox reported on regeneration of the phrenic nerve occurring after damage during coronary artery bypass surgery (CAB) which commonly causes damage through nerve sectioning, stretch, cold exposure and hypoxia leading to axonal degeneration and/or demyelination [5].

In this report, our patient had the diaphragmatic pacemaker placed secondary to phrenic nerve injury *via* radiation, and the resulting recovery of her right phrenic nerve was expected. The diaphragmatic pacer prevented the atrophy of the diaphragm *via* constant electrical stimulation. As a result, this allowed time for the regeneration of the phrenic nerve. Therefore now with a viable right phrenic nerve and a conditioned, non-atrophied hemidiaphragm the patient no longer requires mechanical ventilation *via* the pacemaker.

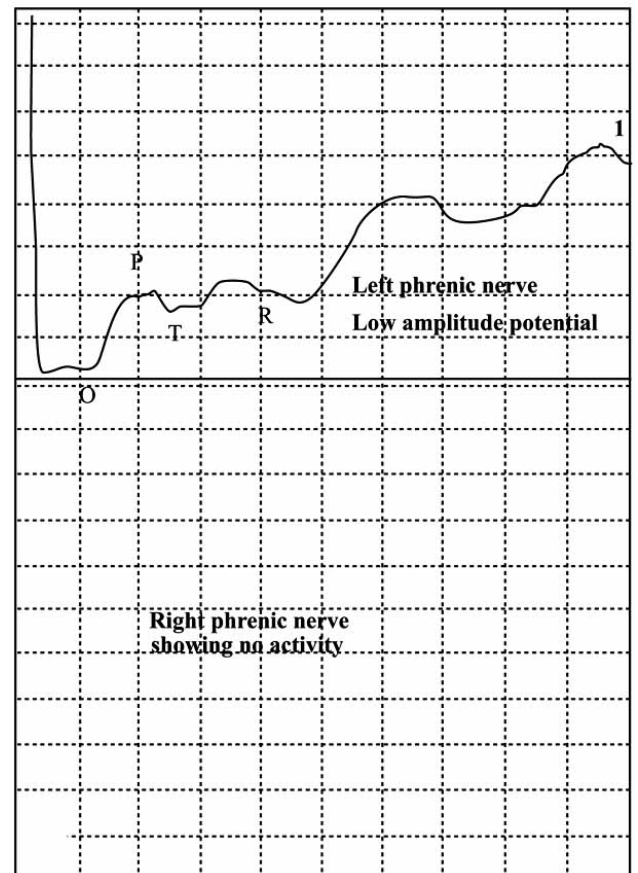
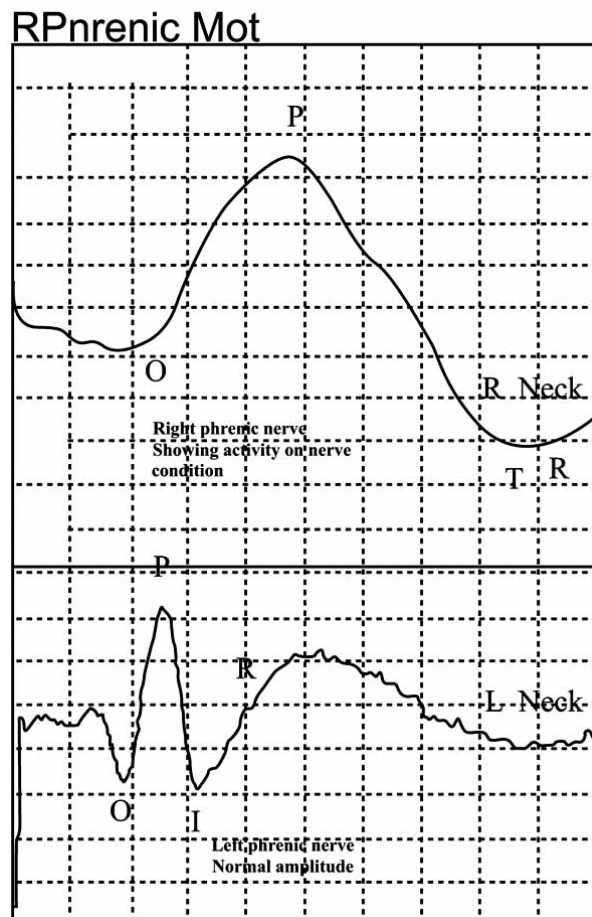


Fig. (1). Showing absence of motor response in right phrenic nerve.



**Fig. (2).** Shows normal motor response to right phrenic nerve stimulation.

## REFERENCES

- [1] Surani S, Afzal A, Elizabeth E, Varon J. Unilateral diaphragmatic pacing: An innovative solution for unilateral diaphragmatic paralysis. *Crit Care Shock* 2007; 10(3):108-110.
- [2] Miller JJ, Farmer JA, Stuart W, Apple D. Phrenic nerve pacing of the quadriplegic patient. *J Thorac Cardiovasc Surg* 1990; 99(1): 35-9
- [3] Pavlovic D, Wendt M. Diaphragm pacing during prolonged mechanical ventilation of the lungs could prevent from respiratory muscle fatigue. *Med Hypotheses* 2003; 60(3): 398-403.
- [4] Broggi G, Franzini A, Borronia V. Phrenic nerve pacing in reversible cervical cord lesion: a case report. *Acta Neurochir (Wien)* 1980; 51(3-4): 273-8.
- [5] Wilcox PD, Pare PD, Pardy RL. Recovery after unilateral phrenic nerve injury associated with coronary artery revascularization. *Chest* 1990; 98: 661-666.
- [6] Verin E, Maria JP, Tardif C, Denis P. Spontaneous recovery of diaphragmatic strength in unilateral diaphragmatic paralysis. *Respir Med* 2006; 100 (11): 1944-51.
- [7] DiMarco AF, Onders RP, Ignagni A, Kowalski KE, Mortimer JT. Phrenic nerve pacing via intramuscular diaphragm electrodes in tetraplegic subjects. *Chest* 2005; 127: 671-678.
- [8] Gariido-Garcia H, Martin-Escribano P, Palomer-Frade J, Arroyo O, Alonso-Calderon JL, Mazaira-Alvarez J. Transdiaphragmatic pressure in quadriplegic individuals ventilated by diaphragmatic pacemaker. *Thorax* 1996; 51 (4): 420-3.9
- [9] Eleftheriades JA, Quin JA, Hogan JF, *et al.* Long-term follow-up of pacing of the conditioned diaphragm in quadriplegia. *Pacing Clin Electrophysiol* 2002; 25 (6): 897-906.
- [10] Garrido-Garcia H, Mazaira AJ, Martin EP, *et al.* Treatment of chronic ventilatory failure using a diaphragmatic pacemaker. *Spinal Cord* 1998; 36 (5): 310-4.
- [11] Hughs PD, Polkey MI, Moxham J, Green M. Long-term recovery of diaphragm strength in neuralgic amyotrophy. *Eur Respir J* 1999; 13: 379-384. 122
- [12] Strokowski JA, Pease WS, Johnson EW. Phrenic nerve stimulation in the evaluation of ventilator-dependent individuals with C4- and C5- level spinal cord injury. *Am J Phys Med Rehabil* 2007; 86: 153-157.