

Clinical Advances in Diaphragm Pacing

Christopher T. Ducko, MD

Abstract: Diaphragmatic pacing is a valuable tool that can significantly benefit certain patients with respiratory insufficiency provided they have an intact phrenic nerve and a functional diaphragm. Careful patient selection is critical to successful long-term results. The main populations that derive benefit from pacing include those with congenital or acquired central hypoventilation syndrome and more commonly those with a high cervical spinal cord injury, where the phrenic nerves remain intact. The pacing electrode of most phrenic nerve pacemakers is implanted directly on the phrenic nerve. A newer device relies on intramuscular implantation of the electrode on the diaphragm at the phrenic nerve motor point. Most patients can be successfully weaned from mechanical ventilation for a substantial time each day, if not completely. This has significant impact on quality of life and implications for healthcare costs. The potential exists for application of this technology to patients with other types of respiratory failure as investigative experience emerges. These include the chronic progressive disease, amyotrophic lateral sclerosis, or temporary scenarios in difficult-to-wean intensive care unit patients. This enabling technology should hold a place in the thoracic surgeon's armamentarium.

Key Words: Diaphragm pacing, Phrenic nerve, Breathing pacemaker, Phrenic nerve motor point, Respiratory insufficiency.

(*Innovations* 2011;6:289–297)

Occasionally, patients with diaphragmatic paralysis are referred for thoracic surgical evaluation. Most of the time, this represents an idiopathic unilateral problem that can be treated with diaphragm plication if necessary. However, in a few select cases, diaphragm pacing is indicated to accomplish weaning from mechanical ventilation or avoid it altogether. Historically, these instances include high cervical spinal cord injury and central hypoventilation syndromes either congenital or acquired; however, other conditions are being explored, including amyotrophic lateral sclerosis (ALS).

Accepted for publication August 26, 2011.

From the Division of Thoracic Surgery, Department of Surgery, Brigham & Women's Hospital, Boston, MA USA.

Supported in part by a grant from the Center for Integration of Medicine and Innovative Technology, Boston, MA USA.

Disclosure: The author declares no conflict of interest.

Address correspondence and reprint requests to Christopher T. Ducko, MD, Division of Thoracic Surgery, Brigham & Women's Hospital, 75 Francis Street, Boston, MA 02115 USA. E-mail: cducko@partners.org.

Copyright © 2011 by the International Society for Minimally Invasive Cardiothoracic Surgery

ISSN: 1556-9845/11/0605-0289

The objective of this article is to review the history of diaphragm pacing, applications where this technology is feasible, current devices available, and techniques used for implantation.

Electrical stimulation of the phrenic nerve as a means of diaphragm pacing was first described in the late 1700s.¹ Since then, electrophrenic pacing has been investigated in various conditions such as asphyxia, cholera, polio, and apnea.² By the end of the 20th century, pioneering work led by Glenn et al.^{3,4} resulted in successful phrenic nerve pacing for patients with high spinal cord injuries and those with congenital central hypoventilation syndrome. More recently, work has focused on the phrenic nerve motor point for more direct diaphragm pacing.⁵ Onders et al.^{6,7} have moved this newer technology forward with innovative applications of diaphragm pacing to other patient populations as well.

DIAGNOSTIC EVALUATION AND PATIENT SELECTION

Although respiratory failure can occur for many reasons, diaphragm pacing is appropriate for only a few select conditions. Careful patient selection is critical for successful long-term outcomes. A thorough history and physical examination with attention to neurologic and pulmonary systems is essential. An intact phrenic nerve and functional diaphragm are mandatory, and in most instances, patients must not have a primary neuromuscular disorder, an underlying restrictive lung disease, or an advanced parenchymal process, where an effective signal could not be conducted or proper oxygenation and ventilation would not occur.⁸ A detailed survey of the cervical spine, neck, and chest via computed tomography is very useful in ruling out an underlying mass lesion or organic pathology. An elevated unilateral hemidiaphragm on chest radiography is suggestive of phrenic nerve paralysis, which is currently not a situation amenable to pacing. These patients should be considered for diaphragm plication.⁹

The gold standard for assessing intact phrenic nerve function is percutaneous cervical electrical stimulation.^{10–12} This study is done by placing an electrode at the lateral edge of the clavicular head of the sternocleidomastoid muscle. The muscle is retracted medially, and a current is directed posteriorly toward the location of the phrenic nerve. An obvious contraction of the diaphragm should follow when the nerve is intact. Failure to conduct or prolonged latency indicates phrenic nerve compromise. Magnetic stimulation is another means of testing the integrity of the phrenic nerve, neuromuscular junction, and diaphragm in a noninvasive fashion. However, this method may be confounded by the body's

ability to lateralize function in the setting of unilateral nerve injury, whereby there may be activation of accessory muscles of respiration or even the contralateral diaphragm.¹³ Phrenic nerve conduction studies should not be done too soon after injury because nerves that are initially responsive may become unresponsive at a later date. Conversely, patients who fail nerve conduction early after spinal cord injury may have recovery on testing conducted up to 2 years after their injury.¹⁴

Another way to assess diaphragm function is via fluoroscopy using the “sniff” test. A functional phrenic nerve produces a brisk downward deflection of the diaphragm when the supine patient sniffs through the nose. Radio-opaque markers are used to measure the maximal excursion of the diaphragm on inspiration. A positive test which confirms phrenic paralysis is seen when there is paradoxical rapid upward motion of the diaphragm during the sniff maneuver.

Once the phrenic nerve, neuromuscular junction, and diaphragm are confirmed to be working, diaphragm pacing can be implemented in patients with partial or total ventilatory insufficiency with the intention of eventually weaning the patient from mechanical ventilation. The conventional candidates for pacing are those patients with high cervical spinal cord injuries or those with congenital central hypoventilation syndrome.¹⁵ In these conditions, the phrenic nerve is still functional. However, the signal required to conduct an impulse from the respiratory centers in the brainstem is missing as a result of the underlying disease; ie, axonal degeneration or idiopathic central disconnect, respectively.

There are an estimated 11,000 new spinal cord injuries annually with approximately 5% resulting in the need for long-term mechanical ventilation.¹⁶ As the phrenic nerve takes off from the C3, 4, and 5 nerve roots, patients injured above this level, ie, C1–2, are tetraplegic. These patients rely on mechanical ventilation but still have an intact nerve.¹⁷ The ability to power the diaphragm by exploiting the intact nerve below the level of injury makes pacing with an external nerve conduction signal an option for weaning these patients from the ventilator.¹⁸ Patients injured below the C5 level may be paraplegic but are capable of breathing on their own. There is variability in the ability to wean from ventilation in those patients whose injuries involve the C3–5 level, and diaphragm pacing with standard techniques is not usually feasible because cell bodies are not viable and nerve axons are unable to conduct a signal. There is a more complex procedure involving nerve transfer that can be effective in reanimating the diaphragm in some of these patients.^{19,20}

Central hypoventilation syndrome is a rare condition in which patients require mechanical ventilation only at night when volitional respiration ceases.^{21,22} The congenital form is also known as Ondine curse which comes from a mythical tale about a water nymph (Onda- Latin for wave) who cursed her mortal husband for his infidelity causing him to cease breathing whenever he should fall asleep. The disconnect between the brainstem respiratory centers and the phrenic nerve can be idiopathic as in the case of congenital central hypoventilation syndrome or it may be acquired as a result of

brainstem stroke, tumor, surgical trauma, hemorrhage, or meningoencephalitis.²²

In either condition, there are significant costs involved in caring for these patients. In addition, there are medical complications, such as ventilator-associated pneumonia, that can detract from overall health. Providing the ability to wean from mechanical ventilation results in an improvement in not only quality of life but also cost savings.^{23,24}

Diaphragm pacing may also be indicated in other less common conditions including intracranial vascular lesions, tumors, central nervous system infections, syringomyelia, and poliomyelitis. Contrary to initial thoughts on phrenic nerve pacing, recently it has been shown that diaphragm pacing may play a valuable role in patients with acute respiratory insufficiency and those with the neuromuscular disease, ALS.^{16,25,26} This paradigm shift may benefit patients by promoting weaning from or delaying the need for mechanical ventilation, respectively. This is especially true because positive pressure ventilation is associated with several drawbacks that include muscle atrophy of the diaphragm, posterior lobe atelectasis due to preferential anterior ventilation, barotrauma as a result of increased airway pressures, and impaired hemodynamics from alterations in venous return.⁷

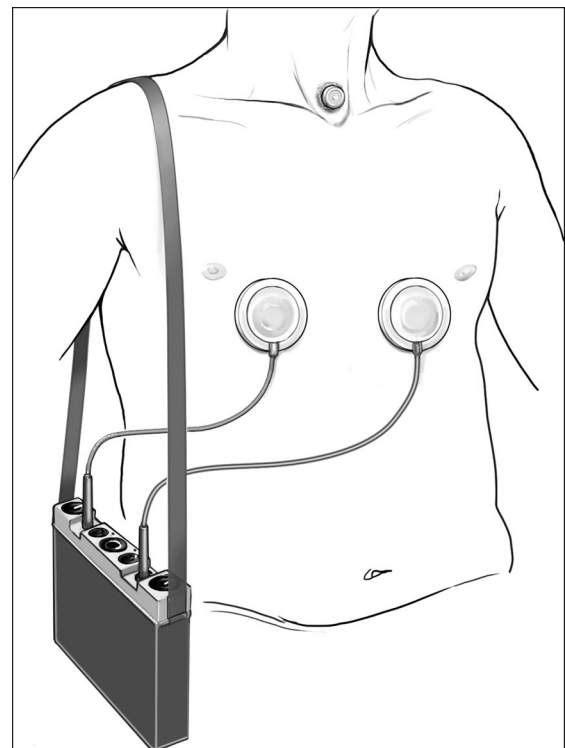


FIGURE 1. Avery Mark IV Phrenic Pacemaker. The external transmitter is connected to antennae on the anterior chest wall and is used to transmit radiofrequency signals across the skin to the implanted receiver, which in turn stimulates the phrenic nerve via the pacing electrode. From Kanaan S and Ducko CT. Disorders of ventilation: diaphragmatic pacing. In (Fauci AS, et al. eds), *Harrison's Online*. Reproduced with permission of McGraw-Hill Professional, NY, Copyright 2010.⁴⁵

DEVICES AND IMPLANTATION TECHNIQUES

Four pacing systems are available worldwide. These include the Vienna Phrenic Pacemaker (Medimplant, Vienna, Austria), the Atrostim (Atrotech Ltd., Tampere, Finland), the Avery Mark IV Phrenic Pacemaker (Avery Biomedical, Commack, NY USA), and the NeuRx Diaphragm Pacing System (DPS; Synapse Biomedical Inc., Oberlin, OH USA). The first three systems are implanted directly on the phrenic nerve and use an external transmitter with antenna to transmit radiofrequency signals transcutaneously to an implanted receiver.²⁷⁻²⁹ The receiver in turn translates the signal into electrical impulses which are delivered to the phrenic nerve electrode to generate contraction of the diaphragm. Diaphragm stimulation and muscle fatigue can be affected by the electrode type which may be unipolar, bipolar, or quadripolar.³⁰ All three systems seem to rely on the same concept and implantation strategies. Of these three, only the Avery device with its monopolar electrode is available in the United States and it will be discussed in this article in more detail (Fig. 1).

Phrenic Nerve Pacing (Avery Mark IV Phrenic Pacemaker)

The Avery pacing device can be implanted in the neck via a cervical approach or in the chest either by open or video-assisted thoracic surgical technique (Figs. 2A, B). In theory, cervical implantation does not capture all potential nerve branches as some accessory phrenic nerve fibers may join the main trunk lower down at the thoracic inlet. This is mostly of theoretical interest as there do not seem to be noticeable differences in pacing ability between levels. An advantage of cervical implantation is the potential for insertion under local anesthetic and the avoidance of double-lumen intubation. Conversely, a potential drawback in locating the incision close to the tracheostomy, which most patients will have in place, is a theoretical increased risk for device infection when compared with implantation in the chest. When using the cervical approach, a transverse incision is made at the base of the neck with the sternocleidomastoid muscle retracted medially. Dissection is carried down laterally where the phrenic nerve is identified superficial to the anterior scalene muscle. The platinum electrode is passed beneath the nerve, and the cuff is anchored with fine polypropylene sutures so that the nerve sits in the cradle with full contact. The lead is then tunneled under the skin above the clavicle and connected to the receiver pocket on the anterior chest wall.

Originally, a full thoracotomy was required for the thoracic approach, but this has been modified over time with advances in minimally invasive access techniques and robotic surgery. The video-assisted thoracic surgical approach can be performed bilaterally in one sitting, as opposed to a staged approach which is sometimes preferable.² A small utility mini-thoracotomy incision is used in the second intercostal space with two thoracoscopy ports inserted in the fifth intercostal space along the midaxillary line and seventh intercostal space along the anterior axillary line. The phrenic nerve is again dissected circumferentially such that the electrode is passed around it and secured to ensure good contact with the

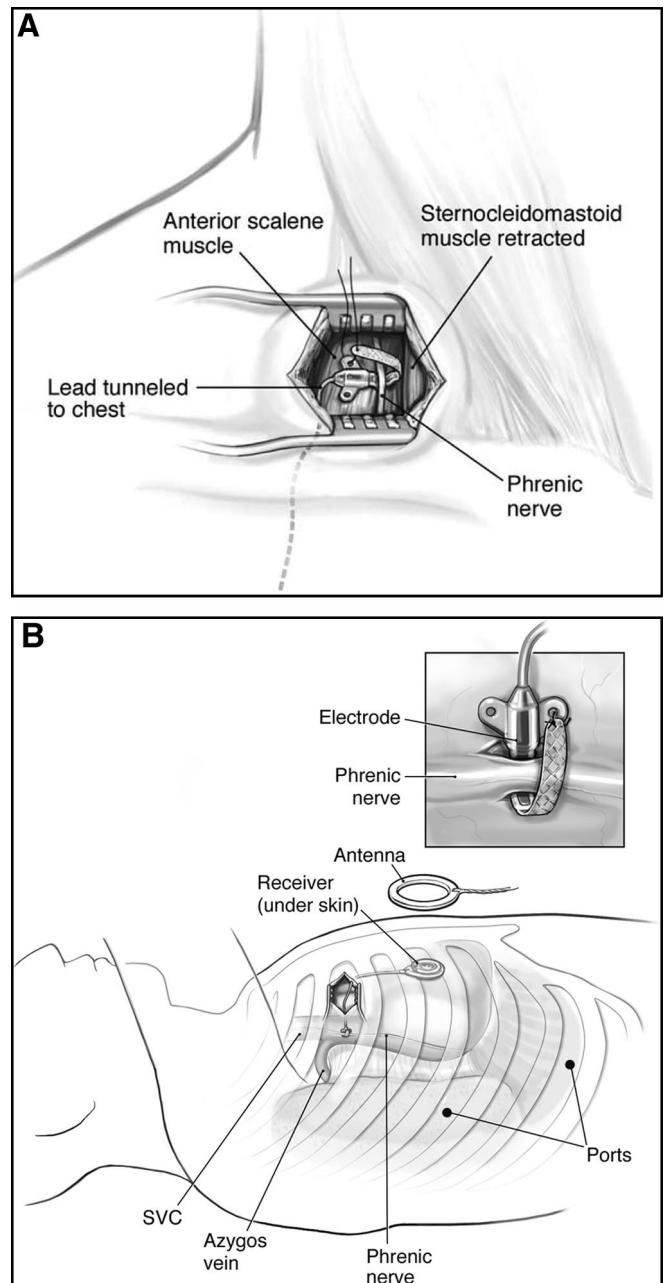


FIGURE 2. A, Cervical approach to placing Avery Mark IV Phrenic Pacemaker. The sternocleidomastoid muscle is retracted medially and the phrenic nerve is identified superficial to the anterior scalene muscle. The electrode is placed beneath the phrenic nerve and the lead is tunneled under the skin of the anterior chest to the receiver. B, Thoracic approach to placing Avery Mark IV Phrenic Pacemaker. The receiver translates radiofrequency signals into electrical impulses, which are carried through the implanted electrode to the phrenic nerve that generates contraction of the diaphragm. The electrode is placed under the phrenic nerve (inset) with care not to injure the nerve. From Kanaan S and Ducko CT. Disorders of ventilation: diaphragmatic pacing. In (Fauci AS, et al. eds), Harrison's Online. Reproduced with permission of McGraw-Hill Professional, NY, Copyright 2010.⁴⁵

nerve. The ideal level for insertion on the right is between the azygos junction with the superior vena cava and the cavoatrial junction. On the left, the preferred site is between the aortic arch and the pulmonary artery.

Regardless of approach, it is important to avoid devascularization of the phrenic nerve during the dissection. To this end, it is useful to leave a 2 to 3 mm rim of perineural tissue intact at the level of nerve dissection. The wire lead from the thoracic electrode exits via a port incision and then is tunneled to the subcutaneous receiver pocket on the anterior chest wall. It is important to leave a coil of slack in the chest to account for lung reexpansion and patient growth, especially in younger children. Diaphragmatic contraction is confirmed, and pacing thresholds are determined before closure. In patients with congenital hypoventilation syndrome who are ambulatory, the receiver pocket is often placed overlying the abdominal wall laterally, whereas in tetraplegic patients the chest wall is more commonly used.

Diaphragm Pacing (NeuRx DPS)

The newest device is the NeuRx DPS, which has been approved by the Food and Drug Administration (FDA) as a humanitarian device exemption since 2008 (Fig. 3). It is available in the United States and many countries. This technology takes advantage of the phrenic nerve motor point at the level of the diaphragm, which is mapped for direct intramuscular electrode implantation. Although it is not fully implantable in its current form, only a few tiny electrode

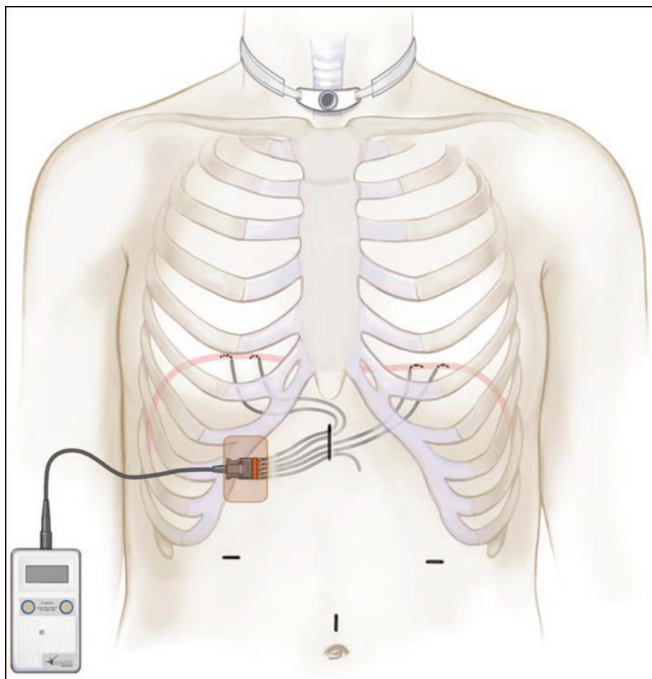


FIGURE 3. NeuRx Diaphragm Pacing System. The device is implanted laparoscopically with two leads inserted in intramuscular fashion into each hemidiaphragm. The leads are tunneled to exit at the skin level where they connect with the stimulator. Device settings for each lead are programmed into the stimulator via a clinical work station (not shown).

leads exit the skin from a subcutaneous tunnel which serves as a barrier to infection.

In addition to avoiding the necessity of inserting leads directly on the phrenic nerve, the DPS implantation is performed laparoscopically and permits insertion of the lead at the phrenic nerve motor point on the underside of the diaphragm. Four ports are used including two 10-mm ports in the supraumbilical and epigastric regions in addition to two lateral 5 mm ports. A portion of the falciform ligament is taken down to improve exposure of both hemidiaphragms. The motor point is then mapped to determine the location of the optimal diaphragm contraction both visually and via pressure measurements using a transducer connected to one of the ports. Once two points of maximal contraction have been mapped on each side for redundancy, electrodes are implanted with a laparoscopic insertion device (Figs. 4A, B). Each lead is loaded into the shaft of the inserter such that the lead is released into the muscle at the mapped motor point when the device needle tip is pulled back and out. It is important to assess for capnothorax should the needle cross into the pleural space. If this occurs, treatment may be unnecessary if proper hemodynamics are maintained. Otherwise, aspiration and/or temporary chest tube insertion may be necessary. The leads are each tested with train stimulations to confirm proper capture and then tunneled out the epigastric port to the right upper quadrant with a fifth subcutaneous lead serving as the ground electrode. The leads are then connected to the stimulator via a small switchboard adapter. Stimulus parameters are programmed into the primary and backup stimulator units using the clinical workstation console. Although the DPS is not completely implantable, as in the case of the phrenic nerve pacemakers, the tunneling serves as a good barrier for infection and the device can be implanted in the outpatient setting with laparoscopic technique.

SET-UP AND PERIOPERATIVE PLANNING

For each device, initial settings are made in the operating room with a specialist from the company present to assist in programming. Pacing thresholds and tidal volumes are determined and set for optimal performance. The conduct of pacing initiation and ventilator weaning is patient-dependent and can vary with pacer device and indication, in addition to the device.^{31,32} Long-term results seem comparable between devices, but the NeuRx patients are able to pace sooner and wean faster. For spinal cord injury patients, where there has been substantial atrophy of the diaphragm and conversion of the type I fatigue-resistant slow twitch muscle fibers to the less efficient type II fast twitch fibers, conditioning needs to occur before full-time pacing can ensue. Progress can be determined by clinical observation of the respiratory work of breathing along with measurements of pulse oximetry, end-tidal CO₂ values, or even arterial blood gases.³³ During a 6-week period of conditioning by electrical stimulation, the force of diaphragm contraction was assessed by measurement of transdiaphragmatic pressures during stimulation of each nerve over a range of frequencies. Tidal volume in addition to rib cage and abdominal motion were studied. There was an upward shift of the force frequency

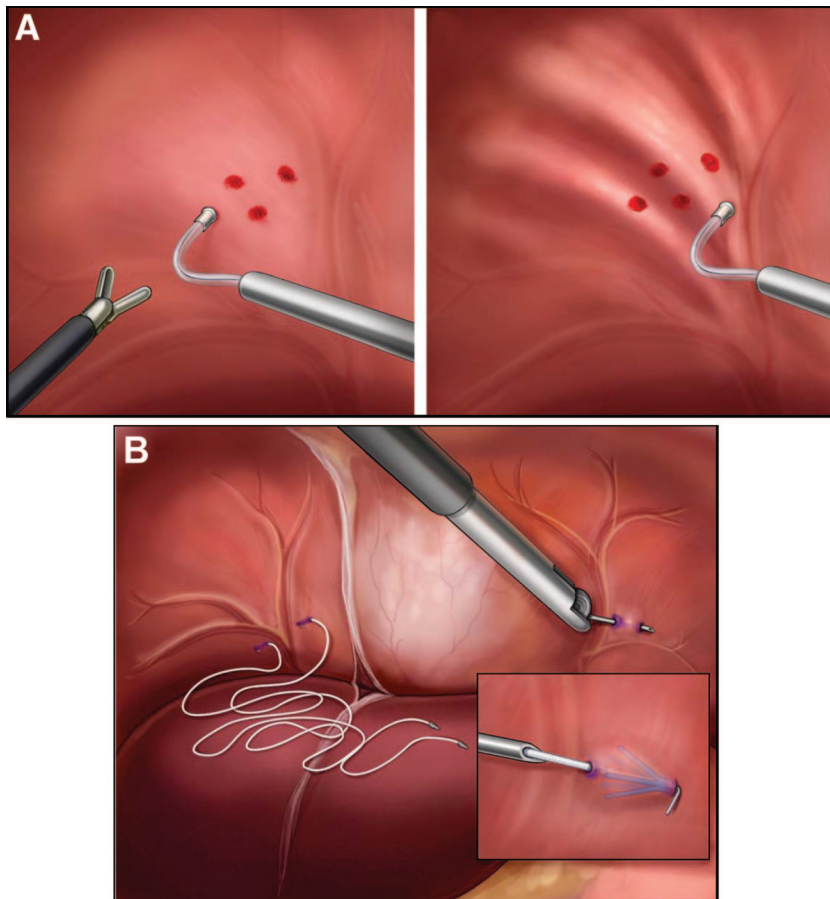


FIGURE 4. A, Diaphragm mapping. Laparoscopic view of right hemi-diaphragm during mapping. The mapping electrode is positioned in different areas (left) and then stimulated (right) until the ideal phrenic nerve motor point is found. The point of maximal contraction is determined by measurement of pneumoperitoneum pressure displacement, tidal volumes generated, and visual inspection. B, Electrode insertion. Two leads are inserted into each hemidiaphragm to optimize diaphragm contraction. The implantation device is carefully inserted into the muscle at the optimal mapping point and then pulled out as the barbs at the tip of each lead hold the wire electrode in place. Care is taken to avoid inadvertent capnothorax.

relationship of the diaphragm over the 4-month period of phrenic nerve pacing using repetitive stimulus trains of 14 to 28 Hz. This improvement seemed to plateau at about 11 weeks. The increase in contractility was accompanied by a progressive diminution in the stimulus frequency at which fusion of the contraction occurred. Full diaphragm conditioning is not necessary in patients with central hypoventilation syndrome as these patients breathe at will during the daytime and have only partial muscle atrophy.³⁴

From a surgical standpoint, it is prudent to communicate in advance plans for implantation with a preassembled patient care team; ie, pulmonologist, rehabilitation physician, respiratory therapist, nursing aides, and/or family members to ensure good coordination of the weaning process. An educational component for the patient, family, and support staff needs to be developed. Establishing a program coordinator or contact person for the implant center can be advantageous to providing continuity in patient care throughout the weaning period, which can range from days to months.

Advantages of natural breathing with either device include simplified nursing care, eventual conversion from tracheostomy to stoma button or even decannulation, reduced intensive care and ventilator-associated pneumonias, improved speech patterns and olfactory sensations, and physical freedom from mechanical ventilation with its attendant disposable supply costs.^{7,18,35,36} After a few years of pacing with

either device, the savings in ventilator supplies and caregiver wages makes the effort cost effective with a favorable return on investment. The Avery device costs approximately \$48,500, whereas the NeuRx device costs approximately \$31,600 for implantation, with less than \$1000 in disposable supply costs per year. This compares favorably to the disposable costs for mechanical ventilation, which average \$1500 per month, such that the return on investment can be seen within 3 years of pacing. The Avery device runs on two 9-V batteries, one for each side. With full-time pacing and typical settings, this correlates to a 6- to 8-week battery life. The NeuRx unit requires a disposable lithium battery which lasts about 3 weeks with full-time pacing. The NeuRx also uses a rechargeable back-up battery that lasts between 8 and 24 hours, and the device will sound a tone when the disposable battery needs to be replaced. Phrenic nerve pacing in spinal cord injury patients reduced not only the incidence of respiratory tract infections but also the costs of respiratory treatments when compared with mechanical ventilation alone.¹⁸ Patients and caregivers must remain vigilant, however, as the underlying condition that required pacer insertion can still be associated with inherent complications related to the natural history of the disease regardless of successful pacing. For instance, spinal cord injury patients who get urinary tract infections will require transient adjustments in pacing parameters during the period of acute infection.

RESULTS

Phrenic Nerve Pacing (Avery Mark IV Phrenic Pacemaker)

Patients usually need a few weeks to recover and for encapsulation of the electrode around the nerve to occur before phrenic nerve pacing ensues. Patients implanted via a cervical approach can often go home the same day. Thoracoscopy patients usually require a few days of hospitalization. The transmitter is used to control the signals to each nerve such that external settings can be adjusted at the bedside in real time. Options include variable amplitude between sides and a single rate. Internal settings include inspiratory time, pulse width, pulse interval, and slope, but these cannot be adjusted directly by the clinician. The system does allow for transtelephonic monitoring whereby the company representative can be available for troubleshooting and adjustments accordingly. A transmitter with new internal settings can be sent on a trial basis before making final changes. Complications include infection (even though the device is fully implantable), injury to the phrenic nerve related to direct implantation, and hardware malfunction. If the device needs to be removed, the electrode must remain in place to avoid damage to the phrenic nerve. A new electrode can be placed around the nerve distally if necessary. Some patients experience obstructive sleep apnea symptoms, and the device is not compatible with magnetic resonance imaging or metal detectors. It can be used in conjunction with a cardiac pacemaker, but specific interrogation of both devices is needed at the time of implantation.³⁷

The Avery system is reliable and has been commercially available in the United States since 1986 following initial FDA approval with some 2000 implants worldwide. A long-term follow-up study from Yale in 2002 reported outcomes in 12 patients implanted for spinal cord injuries between 1981 and 1987.³⁸ Six of the 12 patients were still pacing full-time after a mean of 14.8 years. Although no patient was unable to pace the phrenic nerve, it seems that the other half paced part-time or stopped altogether due in part to extenuating social or financial circumstances as opposed to device-related issues. In those still pacing, threshold currents did not increase over time. One autopsy study showed good preservation of myelin and no significant axonal loss in the phrenic nerve at the site of lead implantation after 10 years of pacing. In many cases, pacing to full-time regimens can require several months and perhaps the longer the time from injury to implantation, the longer it takes to recondition the diaphragm for full-time pacing.

A recent study from Australia confirms the durability of the system with 11 of 19 patients actively pacing over an average duration of 13 years.³⁹ More recent innovations have been applied to spinal cord injuries that cause partial denervation of cell bodies between C-3 and C-5 such that the diaphragm can be reinnervated by nerve transfer methods despite loss of full phrenic nerve function. One technique is quite complicated and involves intercostal nerve harvest for end-to-end microsurgical grafting with the distal phrenic nerve to reanimate the diaphragm, but it has been proven effective in very select patients.¹⁹

Phrenic nerve pacing has been successfully applied to infants and children with central hypoventilation or cervical spinal cord injury. An early study using anterolateral thoracotomy in infants ranging from 2.5 to 8.5 months in age showed feasibility of implantation and safety. All of the eight infants implanted for central hypoventilation syndrome were entirely weaned or significantly decreased from mechanical ventilation at 6 months to 8 years postoperatively.⁴⁰ Thoracoscopic placement has been successful in children with hypoventilation or spinal cord injury ranging in age from 5 to 15 years. Average hospital stay was 4.2 days with 4 of 9 patients experiencing postoperative pneumonia, atelectasis, bradycardia, and pneumothorax. Eight patients reached their long-term pacing goal at early interim follow-up averaging 30 months.⁴¹

Diaphragm Pacing (NeuRx DPS)

Unlike direct phrenic nerve pacers, motor point diaphragm pacing can be initiated almost immediately after implantation, and because the procedure is done laparoscopically, patients can often be discharged the same day. The general stimulus parameter ranges are shown in Table 1. Amplitude and pulse width combine to affect tidal volume and are set for each individual electrode. These values must be sufficient to meet the threshold of excitability of the motor point. Patients with incomplete cord injuries often have pain with pacing. When this occurs, the amplitude is dropped to 20 mA or lower and the pulse width is decreased to 100 μ s or less as tolerated. As patients pace longer and the diaphragm is conditioned, ventilator tidal volumes initially set high for posterior lobe ventilation are reduced to minimize changes in CO₂. Inspiration interval correlates with flow rate on the ventilator to regulate minute ventilation through tidal volume and rate. To avoid electrode corrosion and tetanic contractions, pulse frequency is kept below 20 Hz. Lower frequencies make for strong fused contractions that convert muscle fibers more quickly to fatigue-resistant, type I fibers. Pulse ramp modulates the pulse intensity to smooth the start of each cycle. This device is also compatible with cardiac pacers, provided there is careful intraoperative and postoperative interrogation to monitor for device-to-device interactions. There have been some 250 implants worldwide for all indications.

Onders et al.¹⁶ have documented the success of the DPS system in ventilator-dependent spinal cord injury patients by compiling an excellent report of the multicenter worldwide experience. They concluded that laparoscopic diaphragm mo-

TABLE 1. NeuRx Diaphragm Pacing System: Stimulus Parameter Ranges

Parameter	Range	Starting Point
Amplitude (mA)	5–25	25
Pulse width (μ sec)	20–200	150
Respiration rate (bpm)	8–18	12
Inspiration interval (sec)	0.8–1.5	1.1
Pulse frequency (Hz)	5, 10–20, 30, 50	20
Pulse ramp	0–10	10

tor point mapping, electrode implantation, and pacing can be safely performed whereby 96% of the first 50 patients were able to use the DPS to replace mechanical ventilation for more than 4 continuous hours. More than 50% used the device for continuous 24-hour pacing. There were no perioperative deaths and only one superficial wound infection. Capnothorax, a potential complication of intramuscular lead insertion in the diaphragm, was identified radiographically in 21/50 patients (42%). Although many cases were simply treated with observation, some required uncomplicated intervention via aspiration or small chest tube insertion. Numerous theoretical applications exist for this technology in other types of respiratory failure, because the device is considered to be less invasive and perhaps even temporary when compared with previous phrenic nerve pacemakers where pacing leads are implanted directly on the nerve.^{25,26,42}

Onders et al.⁴³ have also reported experience with diaphragm pacing in, to date, the largest series of surgical patients with ALS. ALS is a progressively fatal disease associated with motor neuron degeneration of the cerebral cortex and impaired mechanical respiratory function. Victims with advanced disease face lifelong positive pressure mechanical ventilation or death. There are probably 5000 new cases of ALS each year, in comparison to 500 patients with high cervical spinal cord injury. This study examined both surgical and anesthetic considerations of DPS implantation and pacing in this unique patient population. For properly selected ALS patients with a suitable forced vital capacity (>50% predicted), the need for mechanical ventilation can be delayed up to 2 years, increasing survival, quality of life, and reducing healthcare costs.

The NeuRx device is currently only FDA-approved for patients older than 18 years.^{42,44} However, investigation is under way showing safe implantation in younger patients. Six children were successfully implanted laparoscopically and ranged in age from 5 to 17 years. Five of the patients underwent a home-based weaning program, and one weaned almost immediately.

DISCUSSION

Diaphragm pacing is an uncommon procedure that thoracic surgeons may be asked to perform. Many patients are referred with unilateral diaphragmatic paralysis related to an idiopathic, viral, or traumatic etiology and do not warrant pacing but actually need diaphragmatic plication instead to improve their dyspnea. For those patients with high cervical spinal cord injury and central hypoventilation, congenital or acquired, it is essential to confirm normal functioning of the phrenic nerve before considering pacing. Fluoroscopy is more widely available and, if possible, should be viewed in person or via cine images. Although it can be associated with user variability and is best done by an experienced neurologic technician or laboratory, a phrenic nerve conduction study is advisable. Discrepancies between studies need to be taken into account by common sense clinical acumen. During implantation of either device, the ability of the phrenic nerve or motor point to conduct a signal is tested and confirmed on the spot before proceeding with full device implantation.

The two basic types of devices involve implantation on the phrenic nerve, itself, or implantation into the diaphragm muscle at the phrenic nerve motor point. Factors that must be considered in selecting the device include surgeon familiarity with implantation techniques such as thoracoscopy versus laparoscopy, and prior surgery or infection such as thoracotomy or laparotomy and empyema or peritonitis, which may limit access to the nerve or motor point. Other comorbidities, such as cardiac disease in adults, certainly apply to any patient regardless of device used.

As these diseases are relatively uncommon, there is unlikely to ever be a trial comparing the two devices. Each has its own advantages and drawbacks, but overall have similar long-term efficacy. Perhaps there should be a call to register patients in a database to share experiences between centers to assist patients and providers to make better informed device selection decisions. It is important to inform patients that although there is the hope and intent of full-time pacing from the outset, there are the intangibles that may make only part-time pacing possible with either device. Centralization of implantation centers does seem worthwhile as is done in other surgical diseases given the low annual volumes of implants. However, if one is carefully proctored in patient selection and live implantation, this is not absolutely necessary. The technicians and representatives from each company are very knowledgeable and supportive in this process.

Currently, the Avery device is fully implantable, whereas the NeuRx relies on electrode wires traversing the skin to the external stimulator. There is inherent risk to the nerve with direct implantation of the electrode as opposed to muscular insertion into the diaphragm at the motor point. This would make the NeuRx device more applicable to instances where temporary pacing would apply, such as following lung surgery on marginal performers or in victims of viral-associated respiratory failure. Just as a cardiac patient, postvalve replacement may need temporary cardiac pacing, thoracic surgical patients with significant emphysema, or following a lung transplant may need a boost in tidal volumes and ventilation after surgery where diaphragm pacing could come into play instead of the patient being reintubated.

Successful pacing can be accomplished with each device, although the NeuRx patients seem to be capable of weaning earlier due to the nature of pacing at the motor point. The time since injury and implantation is inconsequential as long as the nerve is intact, but it may take longer to recondition the diaphragm the further out one is from injury and pacing. Although early implantation may help avoid ventilator-associated pneumonia, there is some time needed for emotional acceptance of the need for mechanical ventilation in the paralyzed spinal cord injury patient, who is usually young and previously healthy. As experience grows with diaphragm pacing for ALS, there may come a time when every patient is considered for implantation early after diagnosis. With either device, some spinal cord patients need or simply prefer part-time mechanical ventilation over full-time pacing perhaps for psychologic comfort, if not for measured hypoventilation.

CONCLUSIONS

Diaphragm pacing is an enabling technology that can significantly benefit carefully selected patients with respiratory insufficiency provided they have an intact phrenic nerve and functional diaphragm. Patients who potentially derive benefits from pacing are primarily those with high cervical spinal cord injury or central hypoventilation syndrome. However, application of this technology to other diseases, such as ALS, is being investigated. Patient selection and preoperative evaluation are crucial to successful, long-term diaphragmatic pacing. A multidisciplinary team approach throughout the perioperative period can help ensure optimal outcomes. Effective diaphragmatic pacing can greatly improve the quality of life for these patients. Furthermore, significant savings in healthcare costs can be realized from this approach.

Newer minimally invasive techniques for pacer implantation and enrollment in a comprehensive pacing program should allow for even better surgical results with fewer complications. Diaphragm pacing has earned a place in the surgeon's armamentarium for select patients with high cervical spinal cord injuries or central hypoventilation syndrome. It will likely prove beneficial to more patients by application in a broader range of circumstances, including innovative applications in ALS, acute lung injuries, lung cancer surgery for patients with marginal lung function, and lung transplantation among others. There is unlikely to ever be a trial comparing the utility between the Avery Mark IV Phrenic Pacemaker and NeuRx DPS devices because of the infrequency of conditions necessitating implantation. Therefore, choice of device should depend on surgeon comfort and familiarity with the various surgical techniques required for implantation, although implantation at the motor point may be more versatile in applications outside spinal cord injury and central hypoventilation populations. Thoracic surgeons should have a basic understanding of this technology and the role it may play in the care of our patients.

REFERENCES

- Schechter DC. Application of electrotherapy to noncardiac thoracic disorders. *Bull N Y Acad Med.* 1970;46:932–951.
- Glenn WW, Phelps ML. Diaphragm pacing by electrical stimulation of the phrenic nerve. *Neurosurgery.* 1985;17:974–984.
- Glenn WW, Holcomb WG, Gee JB, Rath R. Central hypoventilation; long-term ventilatory assistance by radiofrequency electrophrenic respiration. *Ann Surg.* 1970;172:755–773.
- Glenn WW, Holcomb WG, McLaughlin AJ, et al. Total ventilatory support in a quadriplegic patient with radiofrequency electrophrenic respiration. *N Engl J Med.* 1972;286:513–516.
- DiMarco AF, Onders RP, Kowalski KE, et al. Phrenic nerve pacing in a tetraplegic patient via intramuscular diaphragm electrodes. *Am J Respir Crit Care Med.* 2002;166:1604–1606.
- Onders RP, Dimarco AF, Ignagni AR, et al. Mapping the phrenic nerve motor point: the key to a successful laparoscopic diaphragm pacing system in the first human series. *Surgery.* 2004;136:819–826.
- Onders RP. Phrenic nerve and diaphragm motor point pacing. In: Patterson GA, Cooper JD, Deslauriers J, et al, eds. *Pearson's Thoracic and Esophageal Surgery.* 3 ed. Philadelphia, PA: Churchill Livingstone Elsevier; 2008:1445–1457.
- Qureshi A. Diaphragm paralysis. *Semin Respir Crit Care Med.* 2009;30:315–320.
- Ko MA, Darling GE. Acquired paralysis of the diaphragm. *Thorac Surg Clin.* 2009;19:501–510.
- Chervin RD, Guillemainault C. Diaphragm pacing for respiratory insufficiency. *J Clin Neurophysiol.* 1997;14:369–377.
- Shaw RK, Glenn WW, Hogan JF, Phelps ML. Electrophysiological evaluation of phrenic nerve function in candidates for diaphragm pacing. *J Neurosurg.* 1980;53:345–354.
- Alshekhlee A, Onders RP, Syed TU, et al. Phrenic nerve conduction studies in spinal cord injury: applications for diaphragmatic pacing. *Muscle Nerve.* 2008;38:1546–1552.
- Similowski T, Straus C, Attali V, et al. Assessment of the motor pathway to the diaphragm using cortical and cervical magnetic stimulation in the decision-making process of phrenic pacing. *Chest.* 1996;110:1551–1557.
- Lieberman JS, Corkill G, Nayak NN, et al. Serial phrenic nerve conduction studies in candidates for diaphragm pacing. *Arch Phys Med Rehabil.* 1980;61:528–531.
- Glenn WW, Brouillette RT, Dentz B, et al. Fundamental considerations in pacing of the diaphragm for chronic ventilatory insufficiency: a multi-center study. *Pacing Clin Electrophysiol.* 1988;11:2121–2127.
- Onders RP, Elmo M, Khansarinia S, et al. Complete worldwide operative experience in laparoscopic diaphragm pacing: results and differences in spinal cord injured patients and amyotrophic lateral sclerosis patients. *Surg Endosc.* 2009;23:1433–1440.
- Como JJ, Sutton ER, McCunn M, et al. Characterizing the need for mechanical ventilation following cervical spinal cord injury with neurologic deficit. *J Trauma.* 2005;59:912–916.
- Hirschfeld S, Exner G, Luukkaala T, Baer GA. Mechanical ventilation or phrenic nerve stimulation for treatment of spinal cord injury-induced respiratory insufficiency. *Spinal Cord.* 2008;46:738–742.
- Krieger LM, Krieger AJ. The intercostal to phrenic nerve transfer: an effective means of reanimating the diaphragm in patients with high cervical spine injury. *Plast Reconstr Surg.* 2000;105:1255–1261.
- Tubbs RS, Pearson B, Loukas M, et al. Phrenic nerve neurotization utilizing the spinal accessory nerve: technical note with potential application in patients with high cervical quadriplegia. *Childs Nerv Syst.* 2008;24:1341–1344.
- Weese-Mayer DE, Silvestri JM, Menzies LJ, et al. Congenital central hypoventilation syndrome: diagnosis, management, and long-term outcome in thirty-two children. *J Pediatr.* 1992;120:381–387.
- Glenn WW, Haak B, Sasaki C, Kirchner J. Characteristics and surgical management of respiratory complications accompanying pathologic lesions of the brain stem. *Ann Surg.* 1980;191:655–663.
- Stone PW, Braccia D, Larson E. Systematic review of economic analyses of health care-associated infections. *Am J Infect Control.* 2005;33:501–509.
- Edwards JR, Peterson KD, Andrus ML, et al. National Healthcare Safety Network (NHSN) Report, data summary for 2006, issued June 2007. *Am J Infect Control.* 2007;35:290–301.
- Onders RP, Schilz R, Sivashankaran S. Diaphragm pacing as short-term assist to positive pressure mechanical ventilation in critical care patients. *Chest.* 2007;132:571S.
- Pavlovic D, Wendt M. Diaphragm pacing during prolonged mechanical ventilation of the lungs could prevent from respiratory muscle fatigue. *Med Hypotheses.* 2003;60:398–403.
- DiMarco AF, Onders RP, Ignagni A, Kowalski KE. Inspiratory muscle pacing in spinal cord injury: case report and clinical commentary. *J Spinal Cord Med.* 2006;29:95–108.
- Le Pimpec-Barthes F, Gonzalez-Bermejo J, Hubsch JP, et al. Intrathoracic phrenic pacing: a 10-year experience in France. *J Thorac Cardiovasc Surg.* 2011;142:378–383.
- Mayr W, Bijak M, Girsch W, et al. Multichannel stimulation of phrenic nerves by epineural electrodes. Clinical experience and future developments. *ASAIO J.* 1993;39:M729–M735.
- Talonen PP, Baer GA, Hakkinen V, Ojala JK. Neurophysiological and technical considerations for the design of an implantable phrenic nerve stimulator. *Med Biol Eng Comput.* 1990;28:31–37.
- Eleftheriades JA, Quin JA. Diaphragm pacing. *Chest Surg Clin N Am.* 1998;8:331–357.
- DiMarco AF, Onders RP, Ignagni A, et al. Phrenic nerve pacing via

- intramuscular diaphragm electrodes in tetraplegic subjects. *Chest*. 2005; 127:671–678.
33. Nochomovitz ML, Hopkins M, Brodkey J, et al. Conditioning of the diaphragm with phrenic nerve stimulation after prolonged disuse. *Am Rev Respir Dis*. 1984;130:685–688.
 34. Chen ML, Tablizo MA, Kun S, Keens TG. Diaphragm pacers as a treatment for congenital central hypoventilation syndrome. *Expert Rev Med Devices*. 2005;2:577–585.
 35. Shea S. Speech production and speech with a phrenic nerve pacer. *Am J Speech Language Pathology*. 1996;5:55–60.
 36. Adler D, Gonzalez-Bermejo J, Duguet A, et al. Diaphragm pacing restores olfaction in tetraplegia. *Eur Respir J*. 2009;34:365–370.
 37. Kolb C, Eicken A, Zrenner B, Schmitt C. Cardiac pacing in a patient with diaphragm pacing for congenital central hypoventilation syndrome (Ondine's curse). *J Cardiovasc Electrophysiol*. 2006;17:789–791.
 38. Eleftheriades JA, Quin JA, Hogan JF, et al. Long-term follow-up of pacing of the conditioned diaphragm in quadriplegia. *Pacing Clin Electrophysiol*. 2002;25:897–906.
 39. Khong P, Lazzaro A, Mobbs R. Phrenic nerve stimulation: the Australian experience. *J Clin Neurosci*. 2010;17:205–208.
 40. Ilbawi MN, Idriss FS, Hunt CE, et al. Diaphragmatic pacing in infants: techniques and results. *Ann Thorac Surg*. 1985;40:323–329.
 41. Shaul DB, Danielson PD, McComb JG, Keens TG. Thoracoscopic placement of phrenic nerve electrodes for diaphragmatic pacing in children. *J Pediatr Surg*. 2002;37:974–978.
 42. Onders RP, Elmo MJ, Ignagni AR. Diaphragm pacing stimulation system for tetraplegia in individuals injured during childhood or adolescence. *J Spinal Cord Med*. 2007;30 Suppl 1:S25–S29.
 43. Onders RP, Carlin AM, Elmo M, et al. Amyotrophic lateral sclerosis: the Midwestern surgical experience with the diaphragm pacing stimulation system shows that general anesthesia can be safely performed. *Am J Surg*. 2009;197:386–390.
 44. Onders RP, Ponsky TA, Elmo M, et al. First reported experience with intramuscular diaphragm pacing in replacing positive pressure mechanical ventilators in children. *J Pediatr Surg*. 2011;46:72–76.
 45. Kanaan S, Ducko CT. Disorders of ventilation: diaphragmatic pacing. In: Fauci AS, Braunwald E, Kasper DL, eds. *Harrison's Online*. 17 ed. New York: McGraw-Hill Professional; 2010.